



Intraoperative ElectroCorticoGraphy (ECoG): indications, techniques, and utility in epilepsy surgery

Tong Yang¹, Shahin Hakimian², Theodore H. Schwartz^{1,3,4}

¹ Department of Neurosurgery, Weill Cornell Medical College, New York Presbyterian Hospital, New York

² Department of Neurology, Regional Epilepsy Center at Harborview Medical Center, University of Washington Medical Center, Seattle, Washington

³ Department of Neurology and Neuroscience

⁴ Department of Otolaryngology-Head and Neck Surgery, Weill Cornell Medical College, New York Presbyterian Hospital, New York, USA

Received April 29, 2014; Accepted July 16, 2014

ABSTRACT – *Aims.* To describe the technique, indications, and utility of intraoperative ECoG monitoring during various surgeries for medically intractable epilepsy. *Methods.* Literature was reviewed to obtain published results on using intraoperative ECoG techniques for the surgical treatment of medically intractable epilepsy of various underlying aetiologies. *Results.* General intraoperative ECoG techniques were described, including effects of anaesthetic agents on intraoperative ECoG signals. Use of intraoperative ECoG in temporal lobe epilepsy with mesial temporal sclerosis (MTS) is generally considered not necessary, whereas intraoperative ECoG in temporal lobe epilepsy without mesial temporal sclerosis may provide useful information. Intraoperative ECoG in extra-temporal epilepsy with structural lesions may facilitate resection, whereas the use of intraoperative ECoG in extra-temporal epilepsy without a structural lesion is more controversial. *Conclusions.* Intraoperative ECoG is a useful technique to be employed in surgical treatment of medically intractable epilepsy. However, its effectiveness may vary depending on the underlying pathological causes of the seizures.

Key words: electrocorticography (ECoG), intraoperative, temporal lobe epilepsy, extra-temporal epilepsy, medically intractable epilepsy

Correspondence:

Theodore H. Schwartz
Weill Cornell Medical College,
Department of Neurosurgery,
New York Hospital, Box 99,
525 East 68th Street,
New York 10021, USA
<schwarh@med.cornell.edu>

Electroencephalography (EEG) is used to non-invasively monitor electric potentials of the brain through scalp electrodes. It collects signals from the entire brain, but the sensi-

tivity can be low due to interference from the dura, skull, and scalp. When the electrode leads are placed directly over surgically-exposed cortical surface, this monitoring

technique is called electrocorticography (ECoG). This technique was pioneered by Penfield and Jasper at the Montreal Neurological Institute in the early 1950s with the aim to more precisely identify seizure foci and facilitate epilepsy surgery (Penfield and Jasper, 1954). The monitoring can be performed in the operating room for a relatively short duration at the time of surgery; intraoperative ECoG (acute), or can be performed outside the operating room (after surgical electrode implantation) for a longer time (chronic) to capture abnormal electric signals from the brain. ECoG monitoring was found in a survey in 1992 to be used by over 80% of epilepsy surgeons around the world (Engel, 1993).

The guiding principle in epilepsy surgery is to remove the “epileptogenic zone”, or the area of cortex capable of generating seizures. However, the exact definition of the zone is not well established. It is generally accepted that the epileptogenic zone includes the ictal onset zone plus the surrounding “irritative zone”, where frequent interictal discharges are seen (Rasmussen, 1983; Lüders and Awad, 1992; Lüders *et al.*, 1993). Because of the relatively short duration of intraoperative ECoG monitoring, the abnormal signals captured are mostly interictal spikes (*figures 1 and 2*). Only occasionally (most commonly cases of cortical dysplasia), a unique ictal signature can be found within the time frame of intraoperative ECoG recording (Palmini *et al.*, 1995). Otherwise, epileptiform spikes (*i.e.* irritative zone markers) have been used along with other clues (such as those based on imaging) to help identify seizure foci and guide the extent of surgical resections. Although intraoperative ECoG is widely used, its usefulness in locating seizure foci and improving surgical outcomes remains controversial. In fact, use of intraoperative ECoG varies from centre to centre and depending on the underlying seizure aetiology (Keene *et al.*, 2000; Binnie *et al.*, 2001; Kuruvilla and Flink, 2003). This article will discuss the technique of acute intraoperative ECoG, its reported use, advantages, and disadvantages.

Methodology for literature search

The website “Pubmed.gov” was searched using the keyword “intraoperative ECoG”. Recent (last five years) original articles as well as reviews were identified, and the reported findings and conclusions were summarised. Less recent, but relevant, reference papers were gathered from the more recent reference articles. Several textbooks on surgical treatment of epilepsy were also consulted as listed under “References”. The aim of this review was to provide an accessible account of the intraoperative ECoG technique, with a targeted audience of the general practitioners who may be

involved in treating patients with epilepsy. The literature search was not exhaustive and a comprehensive literature review was beyond the scope of this article. There is only one randomised controlled trial article within the reference list (Wiebe *et al.*, 2001). Except for very few prospective case series, almost all the reference articles cited in this review are retrospectively analysed case series. Patient age was not a consideration in the search of the literature.

Intraoperative ECoG monitoring technique

There are two kinds of electrode systems for intraoperative ECoG recordings. The use of either system depends on the individual surgeon’s preference at the time of the operation which includes anatomical considerations for accessibility of recording sites.

For the first kind, arrays of evenly-spaced electrodes are imbedded in “strips” or “grids” of silicone plastic. This type of electrode system is also used for chronic ECoG monitoring. Grids and strips come in standard pre-set sizes but can also be trimmed to accommodate the size and shape of exposed cortical surface. The diameter of each contact electrode is typically 5 mm and the distance between electrodes is typically 1 cm. Because of the presence of the plastic backbone, the brain surface between the electrodes is not accessible for direct stimulation or surgical manipulation until the electrodes are removed. Similarly, the electrodes are a fixed distance apart, and hence some of them may lie over a sulcus or blood vessel, an arrangement that cannot be completely avoided by the surgeon. In recent years, some groups have experimented with more densely arranged microelectrode arrays to potentially improve spatial resolution (Leuthardt *et al.*, 2009). Other modifications such as making holes in the plastic backbone to increase accessibility to the underlying brain, or using heat-sensitive moldable electrodes have been investigated. However, none of the aforementioned modified forms of electrodes are commonly used.

The second kind of electrode system uses a collection of individual rigid wire electrodes held in place over exposed cortical surface and secured in a circular-shaped metal frame that is attached to the skull through a small burr hole. The tip of the electrode that touches the brain surface is covered with electric conductive material, such as carbon. There is typically a spring or other flexible connection between the tip of the electrode and the attachment to the metal frame, so that the electrode can move with the brain surface during normal respiratory cycle without piercing into the brain. Because there is no intervening material between electrodes, the brain surface between

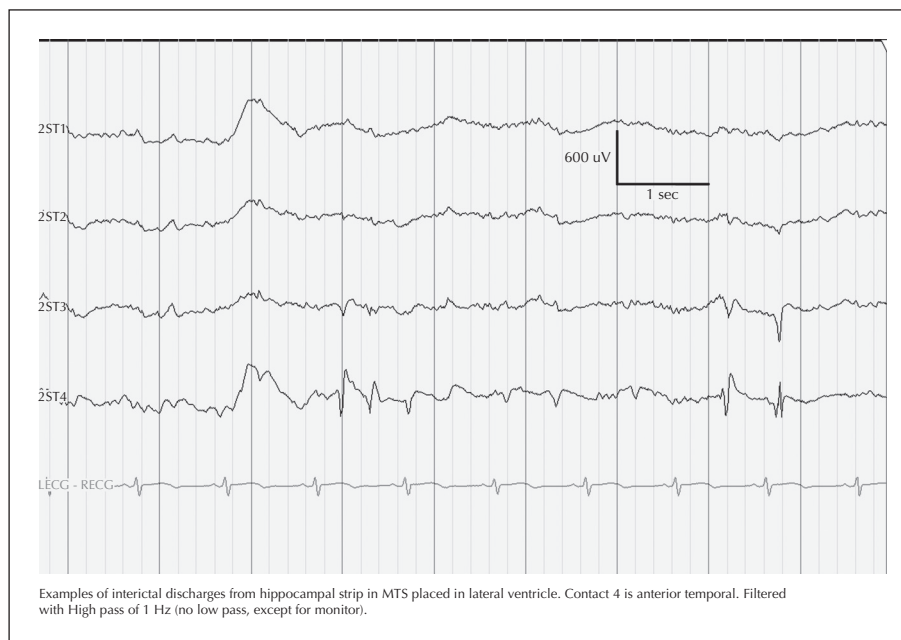


Figure 1. Acute ECoG monitoring of the hippocampus in a patient with medically intractable epilepsy. Interictal spikes were detected in the electrodes covering the anterior portion of the mesial temporal area (MTS) (hippocampus (ST3 and 4) which was resected after the recording, and not in the electrodes covering the posterior portion (ST1 and 2), hence guiding the extent of hippocampal resection.

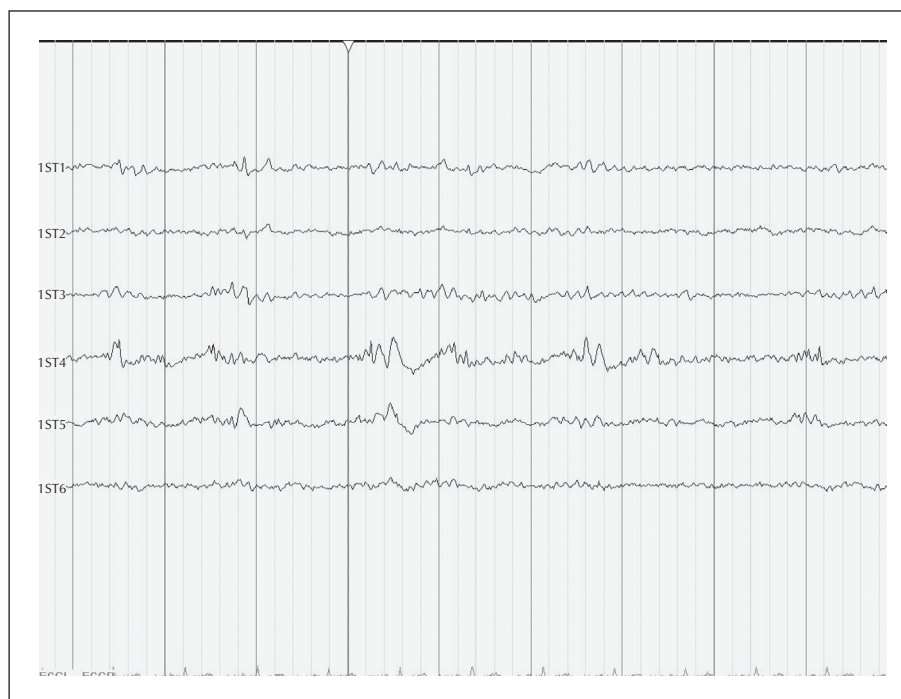


Figure 2. Acute ECoG monitoring of the lateral temporal cortex in a patient with medically intractable epilepsy. Interictal spikes (broad band) with a high-frequency component was detected in a focal electrode (ST4).

the electrodes can be directly stimulated or surgically manipulated while the electrodes are on the surface of the brain, and the location of each electrode can be determined by the surgeon (Nuwer, 1993).

Needle-shaped depth electrodes are also used to monitor deep mesial temporal structures, such as the hippocampus. However, they are not used in the acute ECoG settings due to potential spikes generated from

the acute piercing injury to the brain from the placement of the electrode.

Because of the direct contact of the electrodes to the brain surface, bypassing the interference from the dura, skull, and scalp, ECoG monitoring can detect higher frequency EEG signals than those captured by non-invasive EEG (greater than 60 Hz) (Crone *et al.*, 2006). Recent studies have shown potential use of pathological high-frequency oscillations (pHFOs) as markers for underlying epileptogenic foci (Engel *et al.*, 2009).

The monitoring time typically runs from 5 to 30 minutes, with longer recordings having increased sensitivity to detect infrequent events. Longer recordings also allow more time for anaesthetic effects to dissipate in awake operations, so that the patient is less drowsy, hence activating interictal epileptiform discharges. Abnormal signals can be identified through visual observations by an epileptologist in the operating room. Sometimes, computer programs to recognise certain patterns are used to assist this. Use of pre-resection and post-resection ECoG recordings varies. Both are performed with the aim to identify/confirm seizure foci and to determine the adequate extent of resection. The rate, location, and time of onset of the observed spikes are monitored and analysed.

Some centres have advocated pharmacological activation during intraoperative ECoG recordings (Keene *et al.*, 2000; Binnie *et al.*, 2001). However, the validity of these approaches is not well established, since non-physiological activation can occur, and thus they are not commonly used and will not be discussed here.

Direct cortical stimulation (DCS) of the brain surface using either a hand-held bipolar electrode or the ECoG electrodes themselves, while the ECoG is being recorded from adjacent electrode contacts, can also be performed to determine the threshold for eliciting after-discharges. This information can be used either to identify the seizure focus or as part of functional cortical stimulation mapping (Quesney and Niedermeyer, 1993; Kuruvilla and Flink, 2003). In the former case, a particularly low threshold or provocation of the patient's typical aura may indicate the location of the seizure focus. For brain mapping, avoiding after-discharges is critical to ensure that electrical activation has not spread beyond the electrode tips, and for language mapping, the stimulation amplitude is chosen at an adequately high level, just below the after-discharge threshold, to reduce the incidence of false negative activations. The goal is to use a stimulation amplitude high enough to elicit an effect on a potentially functional cortex, but low enough to avoid a clinical seizure which may confound further mapping and testing during the operation (Quesney and Niedermeyer, 1993; Kuruvilla and Flink, 2003).

Anaesthetic considerations

All agents used in general anaesthesia have effects on intraoperative ECoG signals (Kraemer and Spencer, 1993; Quesney and Niedermeyer, 1993; Sloan, 1998; Keene, 2000). For example, propofol (2,6 di-isopropyl phenol) is a commonly used intravenous form of anaesthetic agent, especially in awake surgeries, due to its short half-life. A recent report (Zijlmans *et al.*, 2012) showed that reduction of the dose of propofol led to increased number of pHFOs captured during intraoperative ECoG recording. Deep anaesthesia may mask the generation of spontaneous abnormal spikes or pHFOs that the intraoperative monitoring is aimed at capturing. As a result, intraoperative ECoG is ideally performed on awake patients under local anaesthesia. However, this regimen may not work for paediatric patients, non-cooperative adults, or patients at risk of hypoventilation (e.g. obese body habitus or obstructive sleep apnoea), and may not be completely necessary if the anaesthetic can be lowered sufficiently. Using light anaesthesia and holding short-acting anaesthetic agents about 10-20 minutes prior to recording can be implemented.

Intraoperative ECoG in temporal lobe epilepsy with mesial temporal sclerosis (MTS)

Temporal lobe epilepsy is a well-defined clinical entity with characteristic symptoms and EEG findings, and non-lesional temporal lobe epilepsy with mesial temporal sclerosis (mesiobasal limbic seizures) is the most common form (Commission, 1989). In 2001, a randomised controlled trial was published on surgery versus medical treatment for temporal lobe epilepsy (Wiebe *et al.*, 2001). In this report, over 70% of the patients had MTS, and surgery was found to lead to 58% of the surgical patients who were free of seizures that impair consciousness versus 8% in the medical group at the end of one year. Together with numerous other publications, this report has established unequivocally that surgery is very effective for temporal lobe epilepsy. In this report and in many surgical centres, standard anteromesial resection (SAMR) with or without minor modification is the surgical approach for temporal lobe epilepsy with MTS (Spencer *et al.*, 1984). The usefulness of intraoperative ECoG in SAMR is equivocal. When MTS patients who had undergone SAMR, regardless of intraoperative ECoG findings, were studied, neither the presence of residual or new post-resection spikes, nor the mean frequency of those spikes correlated with the surgical outcome (Tran *et al.*, 1995; Schwartz *et al.*, 1997). Therefore, it was argued that intraoperative ECoG was not needed for surgeries for

MTS epilepsy (Schwartz, 2006). A recent retrospective case-controlled study of MTS patients showed no difference in surgical outcome between patients with or without residual spikes on post-resection intraoperative ECoG, or between patients who had intraoperative ECoG or SAMR without intraoperative ECoG, thus lending support to the statement that intraoperative ECoG is not necessary for MTS surgery (San-Juan *et al.*, 2011).

On the other hand, the extent of hippocampal resection necessary in MTS surgeries has been debated due to concern for injuries to the patients' memory functions (verbal on the dominant side and non-verbal on the non-dominant side). When the extent of hippocampal resection was tailored based on intraoperative ECoG signals from direct hippocampal monitoring, the rate of seizure control after temporal lobe epilepsy surgery was found to have no correlation with the size of the hippocampus removed (McKhann *et al.*, 2000). Therefore, it was argued that intraoperative ECoG monitoring of the hippocampus was useful for temporal lobe epilepsy surgery to potentially preserve functional hippocampus not involved in seizure genesis, while maintaining the efficacy of the surgery (Ojemann, 2006). Oliveira *et al.* looked at the pattern of intraoperative ECoG obtained during MTS surgery in more detail and found that more complex patterns seen on the recordings might correlate with worse surgical outcome (Oliveira *et al.*, 2006).

Pathological analysis of surgical samples from patients after temporal lobe epilepsy surgery showed a portion of them contained two different pathological processes; cell loss in the hippocampus in addition to lateral temporal lesions. For those samples with heterotopia in the temporal lobe (cortical dysplasia), they tended to be associated with severe cell loss in the hippocampus. Thus, the entity of dual pathology for seizure genesis was proposed (Levesque *et al.*, 1991). Similar to the finding on the usefulness of intraoperative ECoG in surgeries to resect isolated cortical dysplasia for seizure control (Palmini *et al.*, 1995), intraoperative ECoG was found to contribute to the identification of the underlying cortical dysplasia and the determination of the extent of resection in patients with dual pathology (Chacon *et al.*, 2009). Hence, acute ECoG may be useful to rule out dual pathology even in patients with MRI-proven MTS and guide tailored resection of the dysplastic cortex.

Intraoperative ECoG in temporal lobe epilepsy without mesial temporal sclerosis

For patients with temporal lobe epilepsy semiology and scalp-EEG temporal localisation, but no MTS, they

can either have normal MRI or a lesion in the temporal lobe cortex, such as a tumour or a vascular lesion. Patients with normal MRI have been labelled "paradoxical TLE" and shown to have a lower incidence of febrile seizures, a higher incidence of secondary generalised seizures, and less evidence of cell loss on histological examination (Cohen-Gadol *et al.*, 2005). These patients often undergo chronic implantation of electrodes to identify the ictal onset zone prior to resective surgery (Cascino *et al.*, 1995; Siegel *et al.*, 2001; Kuruvilla, 2003; Cohen-Gadol *et al.*, 2005; Oliveira *et al.*, 2006). In spite of these invasive measures, rates of seizure freedom are still lower than those in patients with hippocampal sclerosis on MRI (Schwartz *et al.*, 2006). Chronic ECoG has clearly been shown to be useful in determining the site of seizure onset and the absence of post-resection spikes predictive of clinical outcome (Wyllie *et al.*, 1987; Bautista *et al.*, 1999).

When the time of onset of interictal spikes within a fixed ECoG monitoring duration was analysed, a cluster of "earliest" appearing spikes was localised to the ictal onset zone in 84% of the patients (mix of temporal lobe and extra-temporal lobe epilepsy patients), supporting the use of chronic interictal spikes in temporal epilepsy surgery (Hufnagel *et al.*, 2000). However, the utility of acute intraoperative ECoG is more controversial. Recently, several reports, listed below, found acute ECoG might be useful in temporal epilepsy surgery if more complex signal characteristics were analysed. One group found that the removal of regions with the earliest appearing interictal signals ("leading regions") during ECoG correlated with good seizure control regardless of the underlying pathology (Alarcon *et al.*, 1997). Likewise, clusters of synchronised interictal signals from intraoperative lateral temporal ECoG recordings may be predictive of improved seizure control (patient population is a mixture of those with MTS, temporal lesions or normal imaging findings) (Ortega *et al.*, 2008). A recent study that investigated the value of intraoperative ECoG in TLE with normal MRI showed that all patients with high-amplitude interictal spikes recorded from only the mesial structures went on to have a SAMR, in spite of chronic ECoG. Patients with spikes elsewhere benefited from the chronic ECoG (Luther *et al.*, 2011). This report proposes that intraoperative ECoG can be used to screen patients with TLE and normal MRI, to determine which patients require chronic implantation and which can go directly to SAMR. A retrospective study of 87 patients who had temporal lobe epilepsy, but MRI negative focal findings, showed that the presence of unilateral interictal epileptiform discharges (IEDs) on preoperative scalp EEG, and complete resection of the cortex displaying IEDs on intraoperative ECoG, are the two variables correlated with good seizure control postoperatively (Burkholder *et al.*, 2014).

For patients with lesions, and in particular low-grade tumours associated with intractable TLE, intraoperative ECoG may be used to establish how much adjacent “irritated” cortex around the lesion must be removed to optimise post-operative seizure control. In one report on a mixed population of paediatric and adult patients with seizures due to underlying low-grade gliomas (the majority of which were located in the temporal lobe), intraoperative ECoG was used in all resections to determine the resection margin. The rate of seizure control was found to be superior to historic control when intraoperative ECoG was not used, especially in children (Berger *et al.*, 1993). In another report containing a large patient population with temporal lesions (61 patients with lateral temporal lesions, but 16 patients with MTS were also included and considered to have temporal lesions), 95% of those patients who had good surgical outcome also had concurrent reduction of spikes on post-resection intraoperative ECoG recordings (Tripathi *et al.*, 2010).

From these reports, it appears that intraoperative ECoG may be useful to guide surgical resection of temporal lesions to achieve better seizure control or to predict which patients are more likely to be seizure-free after surgery.

Intraoperative ECoG in extra-temporal epilepsy with structural lesions

Extra-temporal epilepsy may be caused by various underlying aetiologies, such as a structural lesion (developmental [e.g. focal cortical dysplasia], neoplastic [e.g. low-grade glioma], vascular [e.g. cavernous malformation] or other insults [such as previous infection or intracranial haemorrhage]) (Commission, 1989). Various strategies have been proposed including lesionectomy alone versus lesionectomy plus resection of surrounding epileptic zone guided either by acute ECoG or chronic implantation of electrodes (Roper, 2009; Tellez-Zenteno *et al.*, 2010). The second strategy, lesionectomy plus intraoperative ECoG, has been shown in numerous reports to be useful in improving seizure control (Berger *et al.*, 1993; Palmiini *et al.*, 1995; Salanova *et al.*, 1992; Wennberg *et al.*, 1999; Tripathi *et al.*, 2010). Although the general presumption is that the cortex immediately adjacent to the lesion corresponds to the underlying seizure focus, Holmes *et al.* showed that may not always be the case (Holmes *et al.*, 1999). In particular, patients with cortical dysplasia may have a more widespread area of dysplasia than the lesion recognised on MRI (Sisodiya *et al.*, 2009). A retrospective study (Widdess-Walsh *et al.*, 2007) of 48 patients with pathologically-confirmed focal cortical dysplasia showed that complete resection of the ictal onset zone correlated with better seizure control.

Interictal paroxysmal fast runs of spikes captured on intraoperative ECoG recordings was found to correlate with the ictal onset zone, suggesting that acute ECoG was beneficial to the surgical outcome. A recent study (Wang *et al.*, 2013) showed that, for patients with cortical dysplasia and a unique “transmantle” sign on MRI, complete surgical resection of the lesion evident on MRI and intraoperative ECoG recording correlated with seizure freedom postoperatively.

Hence, intraoperative ECoG likely increases resection of potentially epileptogenic cortex and improves seizure control, assuming eloquent cortex is not violated. Chronic implantation of electrodes likely offers additional information, particularly the location of ictal onsets, and permits ictal depth recordings from the hippocampus to evaluate the need for additional mesial resection in cases where a nearby neocortical lesion has rendered the hippocampus independently epileptogenic over time.

Intraoperative ECoG in extra-temporal epilepsy without a structural lesion

Patients with extra-temporal focal epilepsy and no structural lesion have the worst prognosis for seizure freedom. Seizures likely arise from subtle areas of cortical dysplasia that may be multifocal, widespread, and beyond the detection capacities of current imaging modalities. The majority of these patients will require chronic implantation of electrodes, however, a unique intraoperative ECoG signature of microdysplasia has been reported by Palmiini *et al.* consisting of “prolonged trains of rhythmic epileptogenic activity of various patterns” (Palmiini *et al.*, 1995). They used I/CEDs (“ictal or continuous epileptogenic discharges”) to describe them and identified these signals in areas with visible abnormalities seen intraoperatively as well as in surrounding areas that appeared normal to visual inspections. Excision of I/CEDs correlated with favourable seizure control, and acute ECoG is useful in identifying the I/CEDs.

A retrospective study of 102 paediatric patients without focal identifiable structural anomalies on imaging, showed good and long-lasting seizure control after resectional surgery, when the focal preoperative interictal spikes correlated with other preoperative evaluation modalities (such as PET or SPECT) and when the focal cortex-generating interictal spikes on either acute or chronic ECoG was completely removed (Jayakar *et al.*, 2008). Although the role of acute ECoG in the surgical treatment of patients with extra-temporal epilepsy without structural lesion still needs more evaluation, it is foreseeable that acute ECoG will be one component of a multi-modality approach in treating this more challenging form of epilepsy.

Conclusion

Intraoperative ECoG has been used by epilepsy surgeons for over six decades. Controversies exist on the usefulness of this monitoring technique compared with purely anatomical resections (SAMR or lesionectomy) versus chronic implantation of electrodes. For patients with classic mesial temporal epilepsy, the usefulness of intraoperative ECoG is a controversial issue. Standard anteromesial resection reproducibly leads to good seizure control, therefore, intraoperative ECoG may not be necessary. However, centres that perform very selective amygdalohippocampectomies without any neocortical resection may fail to remove small adjacent regions of dual pathology that may be identified with intraoperative ECoG. On the other hand, for lateral temporal or extra-temporal lesional epilepsy, as well as dual pathology temporal lobe epilepsy associated with cortical dysplasia, intraoperative ECoG may provide useful guidance for identifying the lesion, as well as determining the extent of resection. A recent systematic review on seizure control after surgery for supratentorial low-grade gliomas found that only gross-total resection was correlated with seizure control. Tumour location or use of intraoperative ECoG did not affect the surgical outcome (Englot *et al.*, 2011). However, patients with more severe intractable epilepsy were likely selected for ECoG, which biases these retrospective studies.

Intraoperative ECoG has been shown to improve surgical outcomes under certain circumstances, as discussed above. However, its usage is also likely associated with higher cost of the surgery, longer duration of the procedure, and potential complications associated with the invasive nature of the surgery. The situations in which intraoperative ECoG is not needed, or acute ECoG might suffice without the need for chronic implantation of electrodes, are not yet clearly defined in the literature, although using acute ECoG as a screening test for patients who might benefit from more extensive chronic implants has been suggested (Luther *et al.*, 2011). It is foreseeable that a definitive answer will be made from future studies that have better characterised patients with controls, more standardised surgical approach, and intraoperative ECoG regimen, as well as a more objective method of recognition and analysis of the ECoG signals. □

Acknowledgements and disclosures.

The work was not supported by a grant and has not been presented at a meeting. The authors declare that they have no conflicts of interests to report.

References

- Alarcon G, Seoane JJG, Binnie CD, *et al.* Origin and propagation of interictal discharges in the acute electrocorticogram. Implications for pathophysiology and surgical treatment of temporal lobe epilepsy. *Brain* 1997; 120: 2259-82.
- Bautista RE, Cobbs MA, Spencer DD, Spencer SS. Prediction of surgical outcome by interictal epileptiform abnormalities during intracranial EEG monitoring in patients with extrahippocampal seizures. *Epilepsia* 1999; 40: 880-90.
- Berger MS, Ghatan S, Haglund MM, Dobbins J, Ojemann GA. Low-grade gliomas associated with intractable epilepsy: seizure outcome utilizing electrocorticography during tumor resection. *J Neurosurg* 1993; 79: 62-9.
- Binnie CD, Polkey CE, Alarcon G. Electrocorticography. In: Luders HO, Comair YG, eds. *Epilepsy surgery*, 2nd Ed. Philadelphia: Lippincott Williams & Wilkins, 2001, p. 637-41.
- Burkholder DB, Sulc V, Hoffman EM, *et al.* Interictal scalp electroencephalography and intraoperative electrocorticography in magnetic resonance imaging-negative temporal lobe epilepsy surgery. *JAMA Neurol* 2014; 71: 702-9.
- Cascino GD, Trenerry MR, Jack CR Jr, *et al.* Electrocorticography and temporal lobe epilepsy: relationship to quantitative MRI and operative outcome. *Epilepsia* 1995; 36: 692-6.
- Chacon LM, Estupinan B, Pedre LL, *et al.* Microscopic mild focal cortical dysplasia in temporal lobe dual pathology: an electrocorticography study. *Seizure* 2009; 18: 593-600.
- Cohen-Gadol AA, Bradley CC, Williamson A, *et al.* Normal magnetic resonance imaging and medial temporal lobe epilepsy: the clinical syndrome of paradoxical temporal lobe epilepsy. *J Neurosurg* 2005; 102: 902-9.
- Commission on Classification. Terminology of the International League Against Epilepsy. Proposal for revised classification of epilepsies and epileptic syndromes. *Epilepsia* 1989; 30: 389-99.
- Crone NE, Sinai A, Korzeniewska A. High-frequency gamma oscillations and human brain mapping with electrocorticography. *Progress in Brain Research* 2006; 159: 275-95.
- Engel J Jr, Ojemann GA. The next step. In: Engel J Jr, ed. *Surgical treatment of epilepsies*, 2nd Ed. New York: Raven Press, 1993, p. 319-29.
- Engel J Jr, Bragin A, Staba R, Mody I. High-frequency oscillations: what is normal and what is not? *Epilepsia* 2009; 50: 598-604.
- Englot DJ, Berger MS, Barbaro NM, Chang EF. Predictors of seizure freedom after resection of supratentorial low-grade gliomas. *J Neurosurg* 2011; 115: 240-4.
- Holmes MD, Wilensky AJ, Ojemann GA, Ojemann LM. Hippocampal or neocortical lesions on magnetic resonance imaging do not necessarily indicate site of ictal onsets in partial epilepsy. *Ann Neurol* 1999; 45: 461-5.

- Hufnagel A, Dumpelmann M, Zentner J, Schijns O, Elger CE. Clinical relevance of quantified intracranial interictal spike activity in presurgical evaluation of epilepsy. *Epilepsia* 2000;41:467-78.
- Jayakar P, Dunoyer C, Dean P, et al. Epilepsy surgery in patients with normal or nonfocal MRI scans: Integrative strategies offer long-term seizure relief. *Epilepsia* 2008;49:758-64.
- Keene DL, Whiting S, Ventureyra ECG. Electrocorticography. *Epileptic Disord* 2000;2:57-64.
- Kraemer D, Spencer DD. Anesthesia in epilepsy surgery. In: Engel J Jr, ed. *Surgical treatment of epilepsies*, 2nd ed. New York: Raven Press, 1993, p. 527-38.
- Kuruvilla A, Flink R. Intraoperative electrocorticography in epilepsy surgery: useful or not? *Seizure* 2003;12:577-84.
- Leuthardt EC, Freudenberg Z, Bundy D, Roland J. Microscale recording from human motor cortex: implications for minimally invasive electrocorticographic brain-computer interfaces. *Neurosurg Focus* 2009;27:E10.
- Levesque MF, Nakasato N, Vinters HV, Babb TL. Surgical treatment of limbic epilepsy associated with extrahippocampal lesions: the problem of dual pathology. *J Neurosurg* 1991;75:364-70.
- Luders HO, Awad I. Conceptual considerations. In: Luders HO, ed. *Epilepsy surgery*. New York: Raven Press, 1992, p. 51-62.
- Luders HO, Engel J Jr, Munari C. General principles. In: Engel J Jr, ed. *Surgical treatment of epilepsies*. New York: Raven Press, 1993, p. 137-53.
- Luther N, Rubens E, Sethi N, et al. The value of intraoperative electrocorticography in surgical decision making for temporal lobe epilepsy with normal MRI. *Epilepsia* 2011;52:941-8.
- McKhann II GM, Schoenfeld-McNeill J, Born DE, Haglund MM, Ojemann GA. Intraoperative hippocampal electrocorticography to predict the extent of hippocampal resection in temporal lobe epilepsy surgery. *J Neurosurg* 2000;93:44-52.
- Nuwer MR. Intraoperative electroencephalography. *J Clin Neurophysiol* 1993;10:437-44.
- Ojemann GA. Intraoperative electrocorticography is useful in temporal resection. In: Miller JW, Silbergeld DL, eds. *Epilepsy surgery: principles & controversies*. New York: Taylor & Francis, 2006, p. 435-8.
- Oliveira PAL, Garzon E, Caboclo LOSF, et al. Can intraoperative electrocorticography patterns predict surgical outcome in patients with temporal lobe epilepsy secondary to unilateral mesial temporal sclerosis? *Seizure* 2006;15:541-51.
- Palmini A, Gambardella A, Andermann F, et al. Intrinsic epileptogenicity of human dysplastic cortex as suggested by corticography and surgical results. *Ann Neurol* 1995;37:476-87.
- Penfield W, Jasper H. Electrocorcography. In: Penfield W, Jasper H, eds. *Functional anatomy of the human brain*. Boston: Little Brown, 1954, p. 692-738.
- Ortega GJ, Menendez de la Prida L, Sola RG, Pastor J. Synchronization clusters of interictal activity in the lateral temporal cortex of epileptic patients: intraoperative electrocorticographic analysis. *Epilepsia* 2008;49:269-80.
- Quesney LF, Niedermeyer E. Electrocorcography. In: Niedermeyer E, Lopes da Silva F, eds. *Electroencephalography: basic principles, clinical applications and related fields*. Baltimore: Williams & Wilkins, 1993, p. 695-9.
- Rasmussen T. Characteristics of a pure culture of frontal lobe epilepsy. *Epilepsia* 1983;24:482-93.
- Roper SN. Surgical treatment of the extratemporal epilepsies. *Epilepsia* 2009;50:69-74.
- Salanova V, Andermann F, Olivier A, Rasmussen T, Quesney LF. Occipital lobe epilepsy: electroclinical manifestations, electrocorticography, cortical stimulation and outcome in 42 patients treated between 1930 and 1991. Surgery of occipital lobe epilepsy. *Brain* 1992;115:1655-80.
- San-juan D, Alfaro CT, Gonzalez-Aragon MF, Martinez AM, J Staba R, Alonso-Vanegas M. The prognostic role of electrocorticography in tailored temporal lobe surgery. *Seizure* 2011;20:564-9.
- Schwartz TH, Bazil CW, Walczak TS, Chan S, Pedley TA, Goodman RR. The predictive value of intraoperative electrocorticography in resection for limbic epilepsy associated with mesial temporal sclerosis. *Neurosurgery* 1997;40:302-11.
- Schwartz TH. Intraoperative electrocorticography has a limited role in the treatment of nonlesional medial temporal lobe epilepsy. In: Miller JW, Silbergeld DL, eds. *Epilepsy surgery: principles & controversies*. New York: Taylor & Francis, 2006, p. 438-41.
- Schwartz TH, Jeha L, Tanner A, Bingaman W, Sperling MR. Late seizures in patients initially seizure free after epilepsy surgery. *Epilepsia* 2006;47:567-73.
- Siegel AM, Jobst BC, Thadani VM, et al. Medically intractable localization-related epilepsy with normal MRI: presurgical evaluation and surgical outcome in 43 patients. *Epilepsia* 2001;42:883-8.
- Sisodiya SM, Fauser S, Cross JH, Thom M. Focal cortical dysplasia type II: biological features and clinical perspectives. *Lancet Neuro* 2009;8:830-43.
- Sloan TB. Anesthetic effects on electrophysiologic recordings. *J Clin Neurophysiol* 1998;15:217-26.
- Spencer DD, Spencer SS, Mattson RH, Williamson PD, Novelly RA. Access to the posterior medial temporal lobe structures in the surgical treatment of temporal lobe epilepsy. *Neurosurgery* 1984;15:667-71.
- Tellez-Zenteno JF, Ronquillo LH, Moien-Afshari F, Wiebe S. Surgical outcomes in lesional and non-lesional epilepsy: a systematic review and meta-analysis. *Epilepsy Research* 2010;89:310-8.

Tran TA, Spencer SS, Marks D, Javidan M, Pacia S, Spencer DD. Significance of spikes recorded on electrocorticography in nonlesional medial temporal lobe epilepsy. *Ann Neurol* 1995; 38: 763-70.

Tripathi M, Garg A, Gaikwad S, *et al.* Intra-operative electrocorticography in lesional epilepsy. *Epilepsy Research* 2010; 89: 133-41.

Wang DD, Deans AE, Barkovich AJ, *et al.* Transmantle sign in focal cortical dysplasia: a unique radiological entity with excellent prognosis for seizure control. *J Neurosurg* 2013; 118: 337-44.

Wennberg R, Quesney LF, Lozano A, Olivier A, Rasmussen T. Role of electrocorticography at surgery for lesion-related frontal lobe epilepsy. *Can J Neurol Sci* 1999; 26: 33-9.

Widess-Walsh P, Jeha L, Nair D, Kotagal P, Bingaman W, Najm I. Subdural electrode analysis in focal cortical dysplasia: predictors of surgical outcome. *Neurology* 2007; 69: 660-7.

Wiebe S, Blume WT, Girvin JP, Eliasziw M. A randomized controlled trial of surgery for temporal-lobe epilepsy. *N Engl J Med* 2001; 345: 311-8.

Wyllie E, Luders HO, Morris HH 3rd, *et al.* Clinical outcome after complete or partial cortical resection for intractable epilepsy. *Neurology* 1987; 37: 1634-41.

Zijlmans M, Huiskamp GM, Cremer OL, Ferrier CH, van Huf-felen AC, Leijten FS. Epileptic high-frequency oscillations in intraoperative electrocorticography: the effect of propofol. *Epilepsia* 2012; 53: 1799-809.

TEST YOURSELF



1. What is intraoperative ECoG?
2. What is the use of intraoperative ECoG in temporal lobe epilepsy with mesial temporal sclerosis (MTS) versus without MTS?
3. What is the use of intraoperative ECoG in extra-temporal epilepsy with abnormal MRI versus without abnormal MRI?

Note: Reading the manuscript provides an answer to all questions. You can check for the correct answer by visiting the Educational Centre section of www.epilepticdisorders.com